

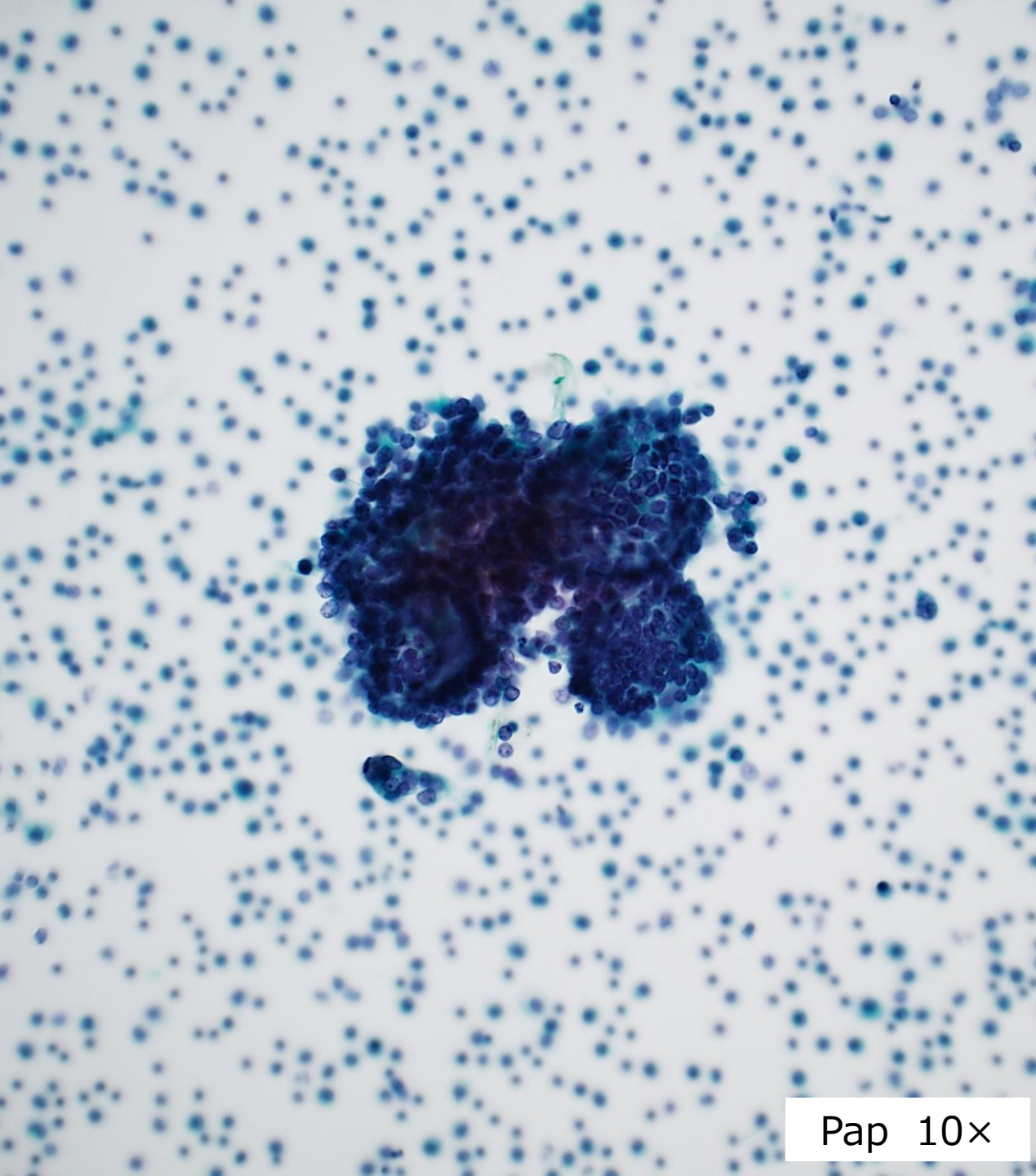
CASE STUDY

Patient: 67-year-old female

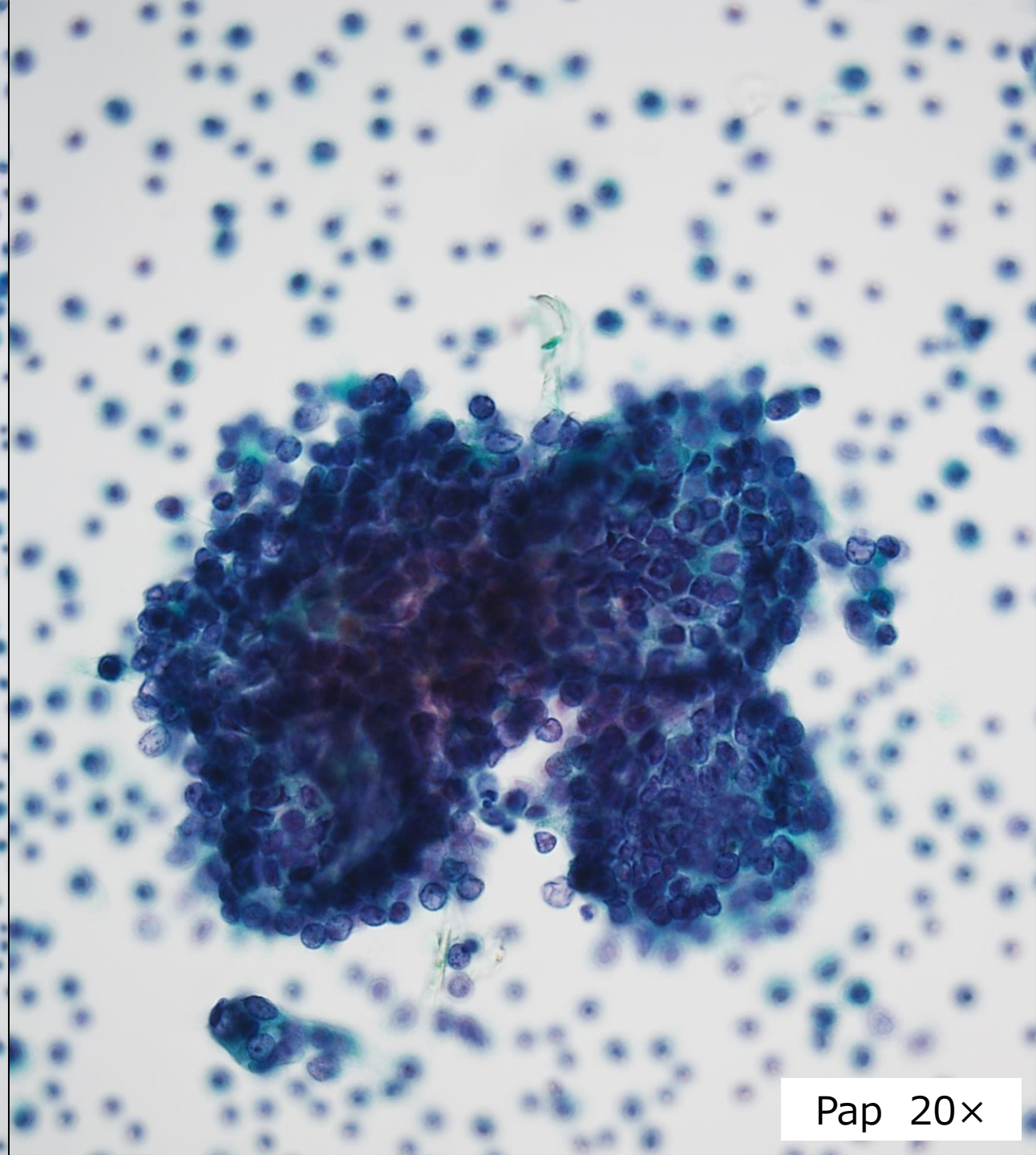
Chief complaint: liver dysfunction

History: Liver dysfunction was noted during a medical checkup,
and an intra-abdominal mass was found on abdominal
ultrasound

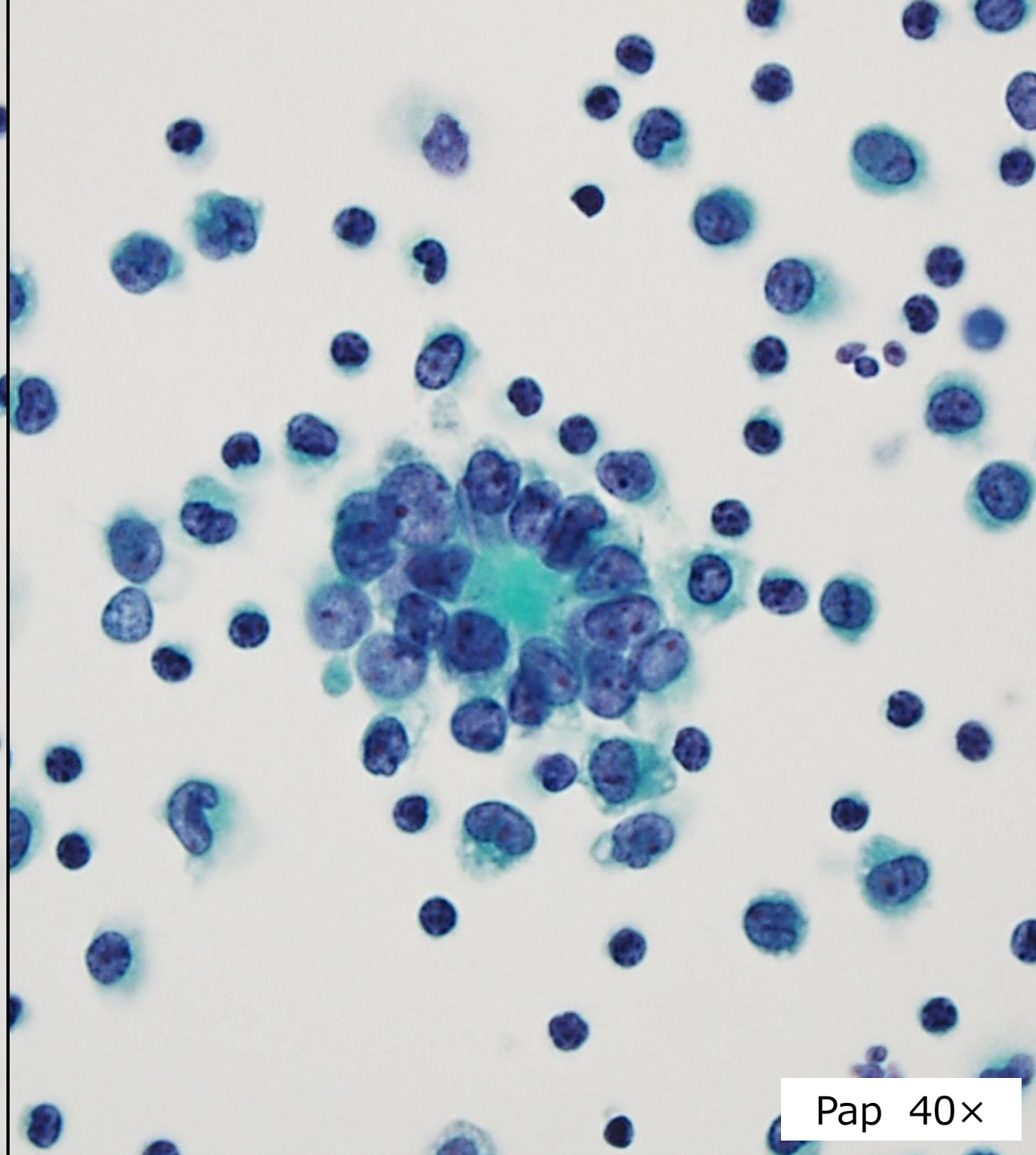
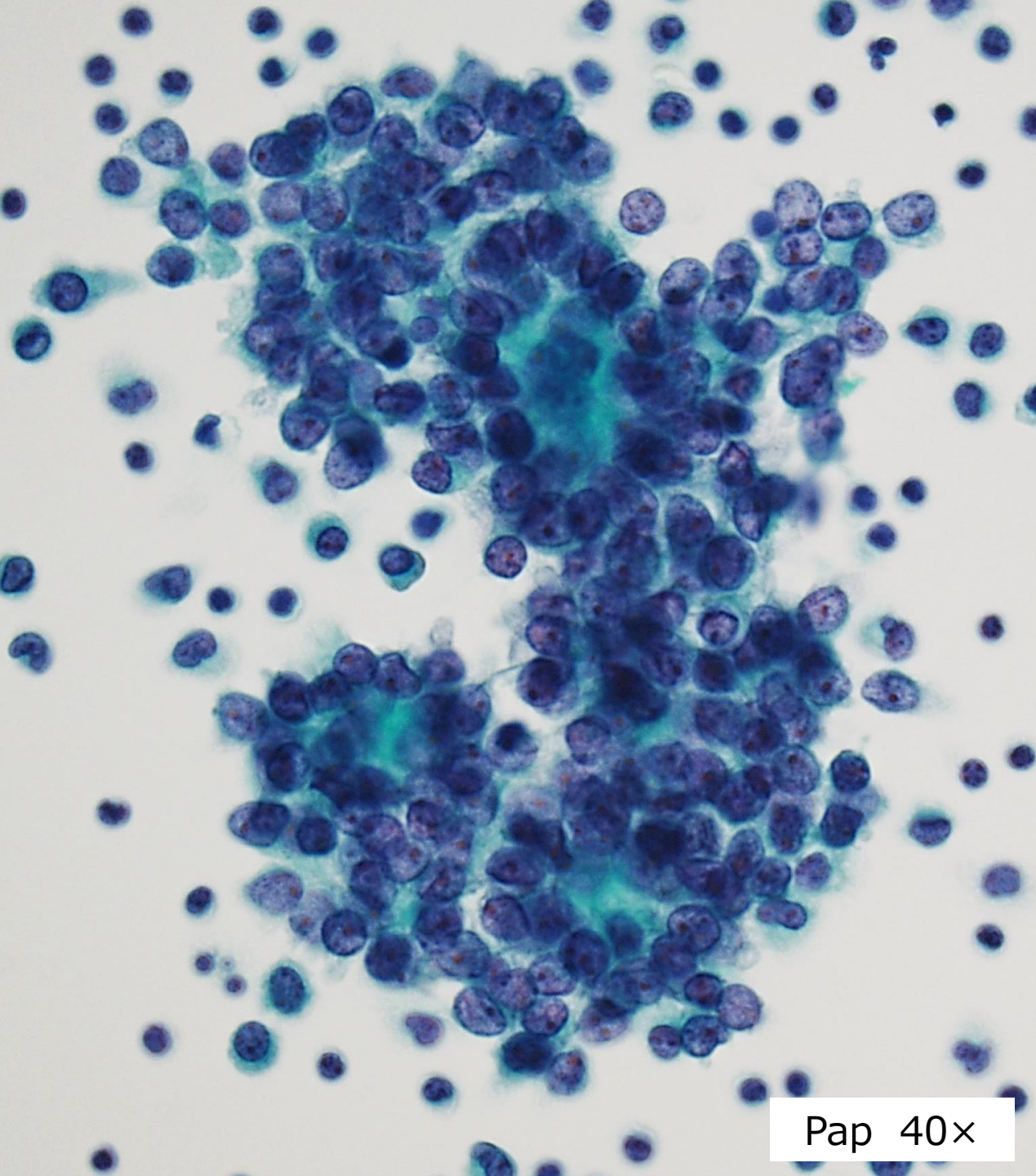
Specimen: ascites

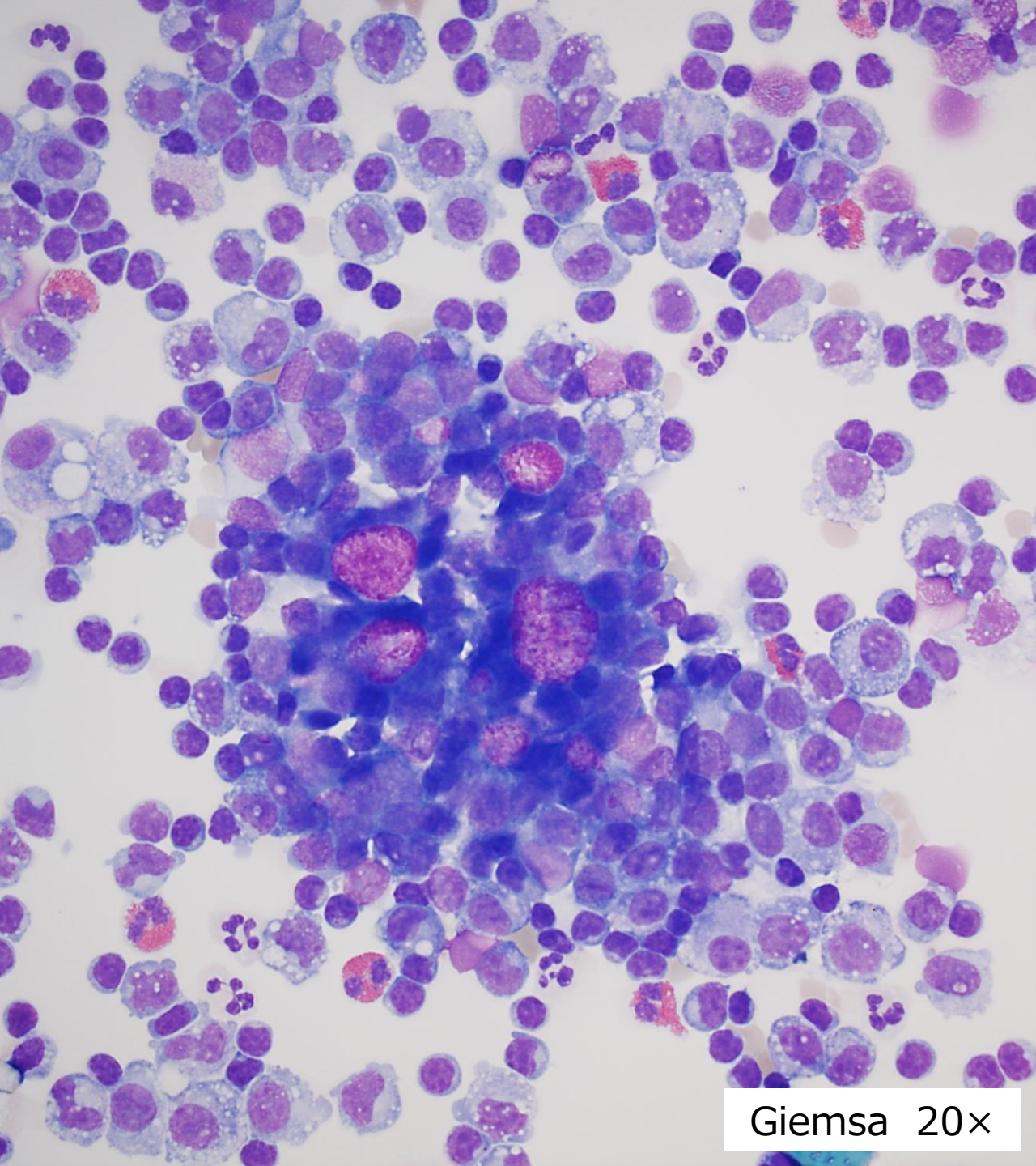


Pap 10x

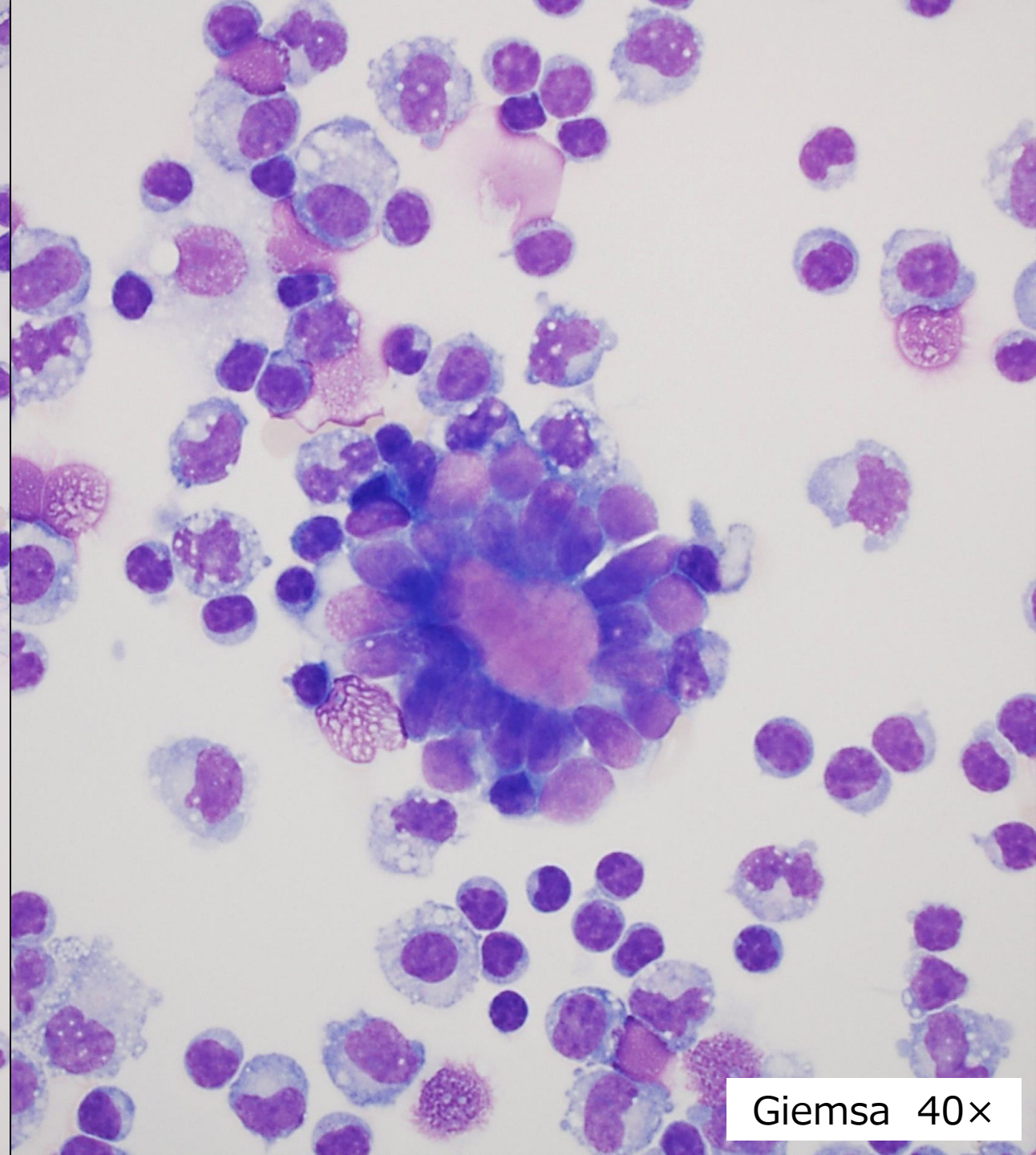


Pap 20x





Giemsa 20×



Giemsa 40×

Diagnosis

1. Adenocarcinoma
2. Granulosa cell tumors
3. Thecoma
4. Sertoli-Leydig cell tumors
5. Neuroendocrine tumor