

The 63rd Annual Autumn Meeting of Japanese Society of Clinical Cytology
Global Asian Forum
November 17th, 2024

Case Presentation

Satoshi Morito¹⁾, Saori Yoshioka¹⁾,
Eri Shimada²⁾, Hiroshi Yasui²⁾

1) Department of Clinical Laboratory, Rakuwakai Otowa Hospital

2) Department of Diagnostic Pathology, Rakuwakai Otowa Hospital

Case

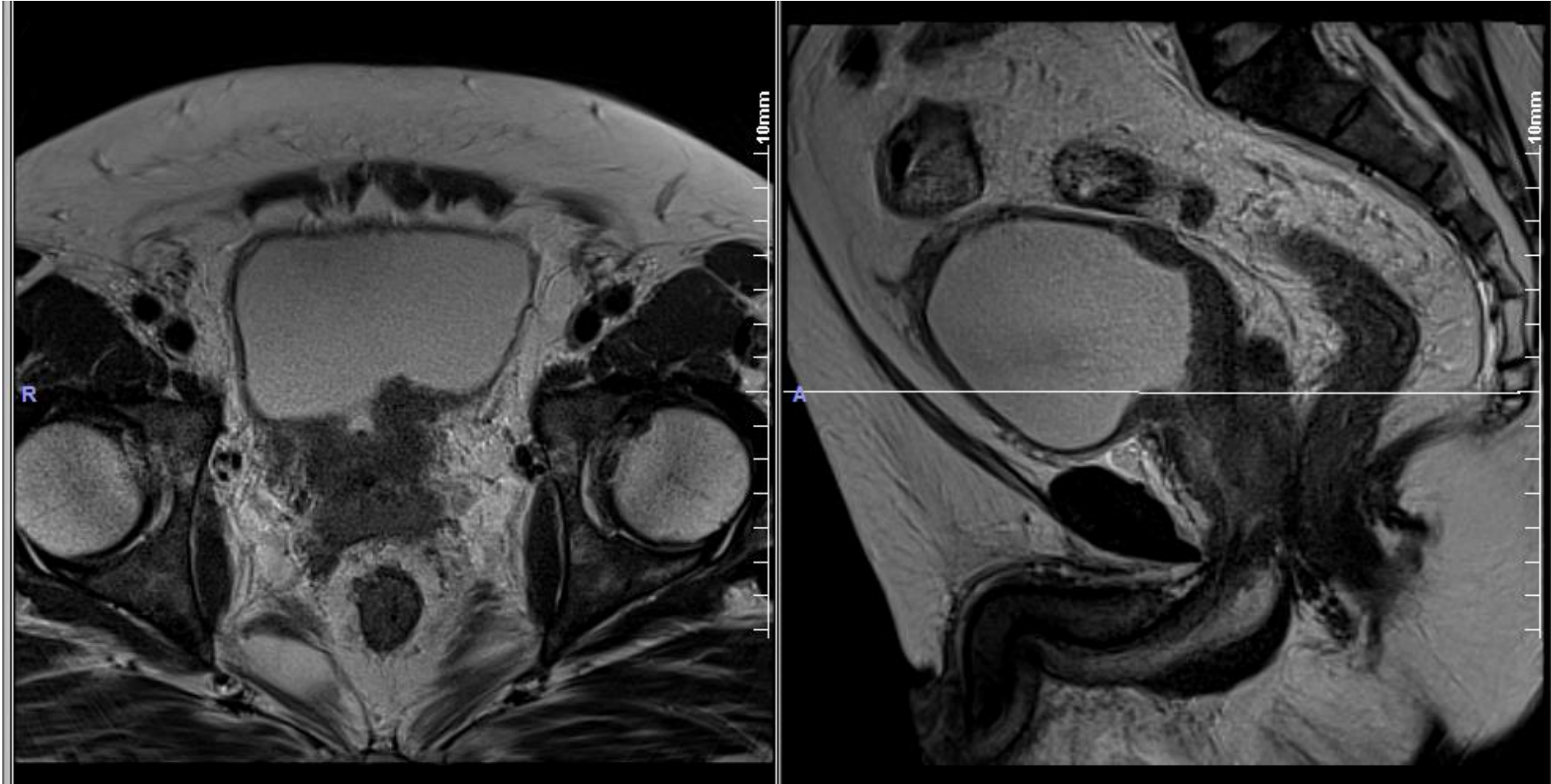
Patient: 40y, male

Symptoms: lower abdominal pain, dysuria

Laboratory Examination: PSA=126.9ng/mL

MRI

(T2-enhanced)



Prostate: enlargement (+)

Bladder trigone: wall thickening (+)

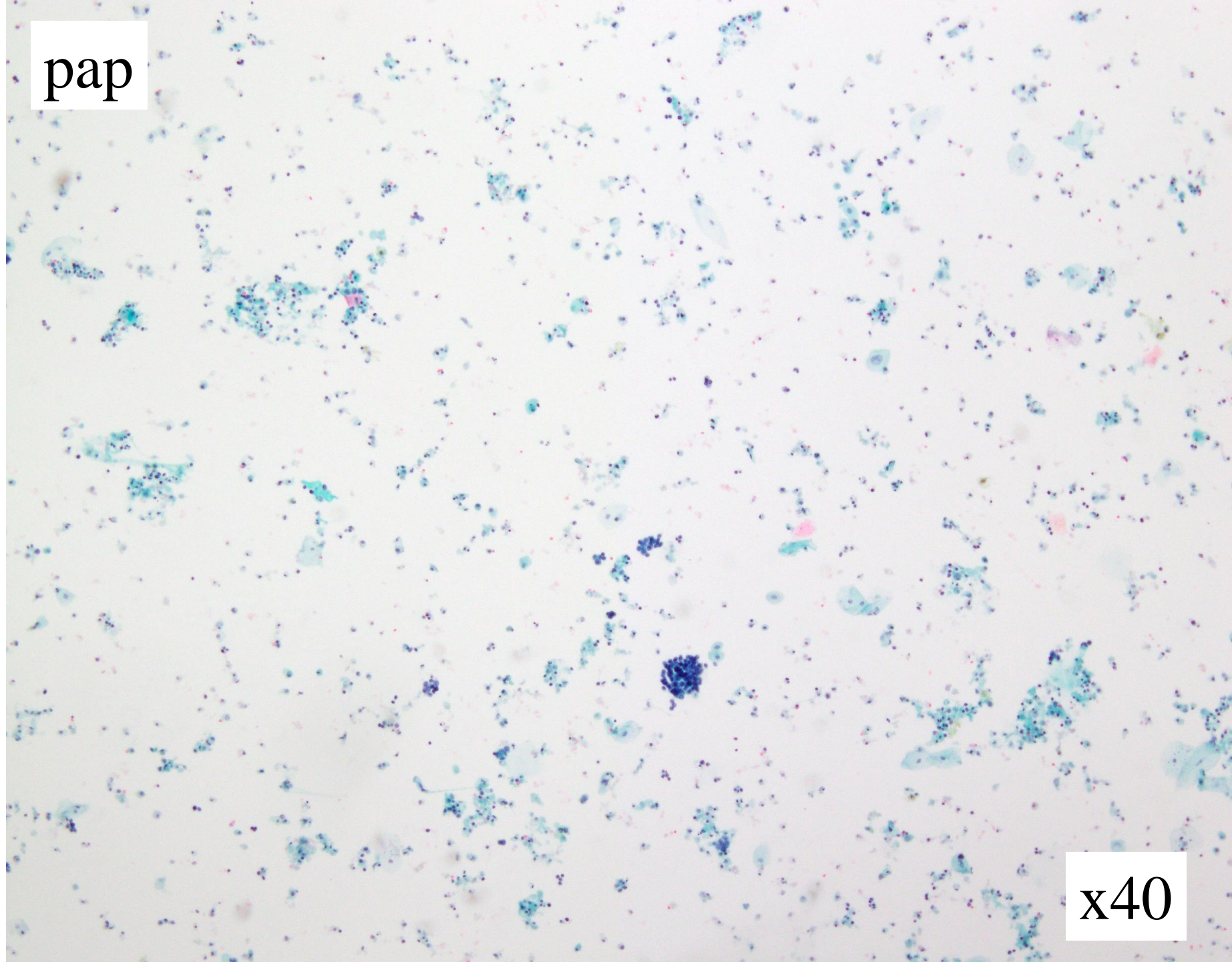
Cytology

Specimen: Urine

Preparation: liquid based cytology (Cellprep)

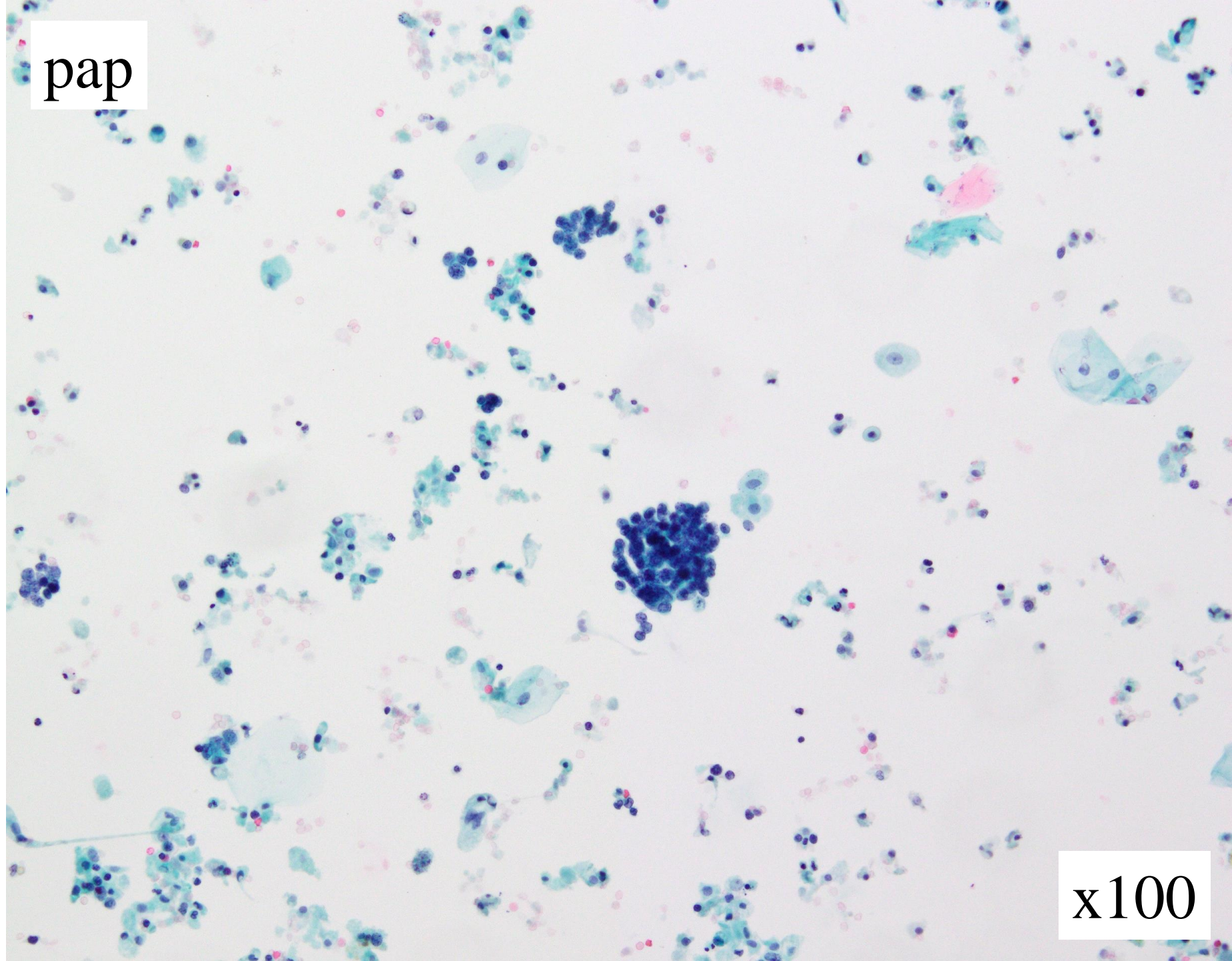
* Pre-Fixation: TACAS™ Ruby

pap



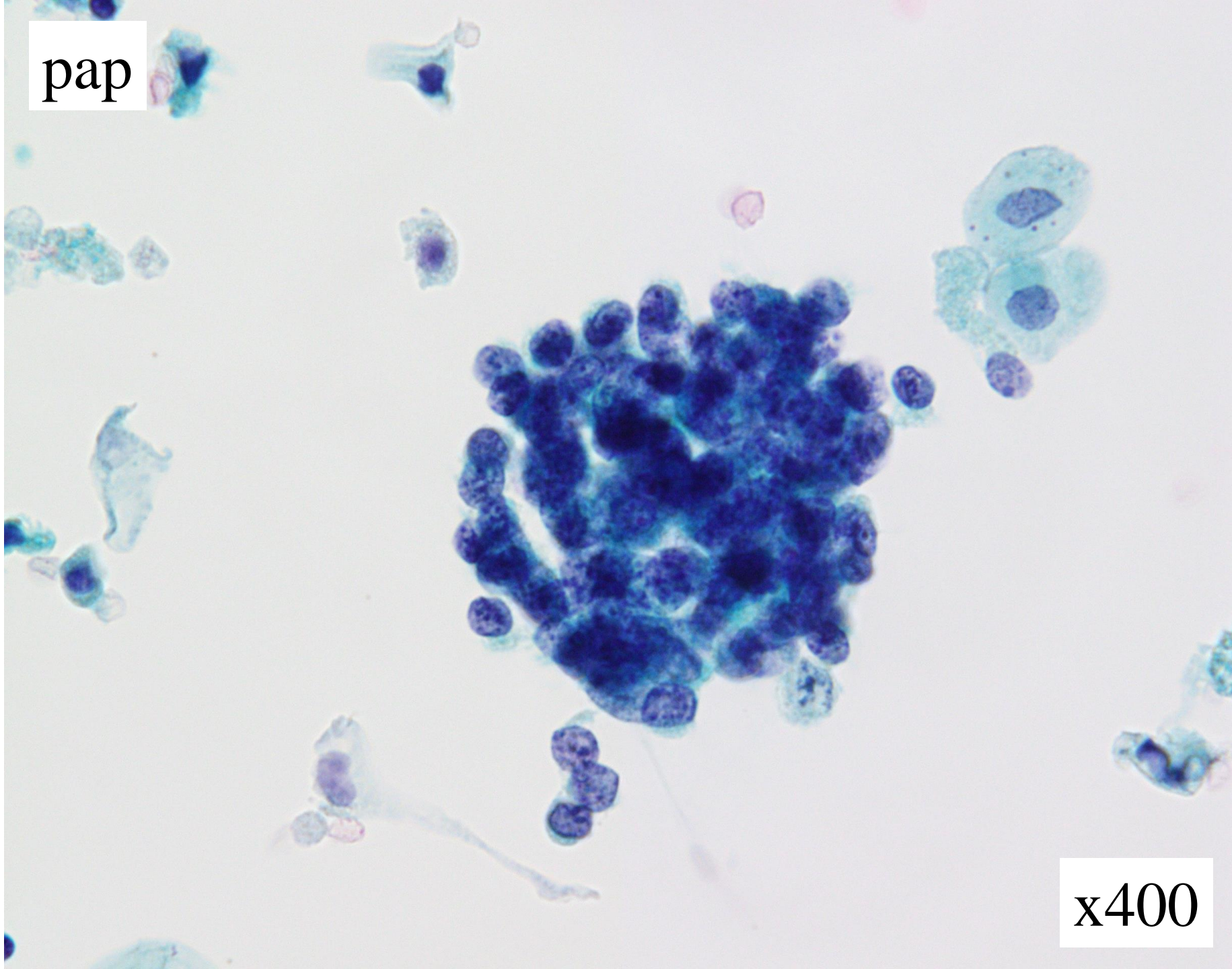
x40

pap



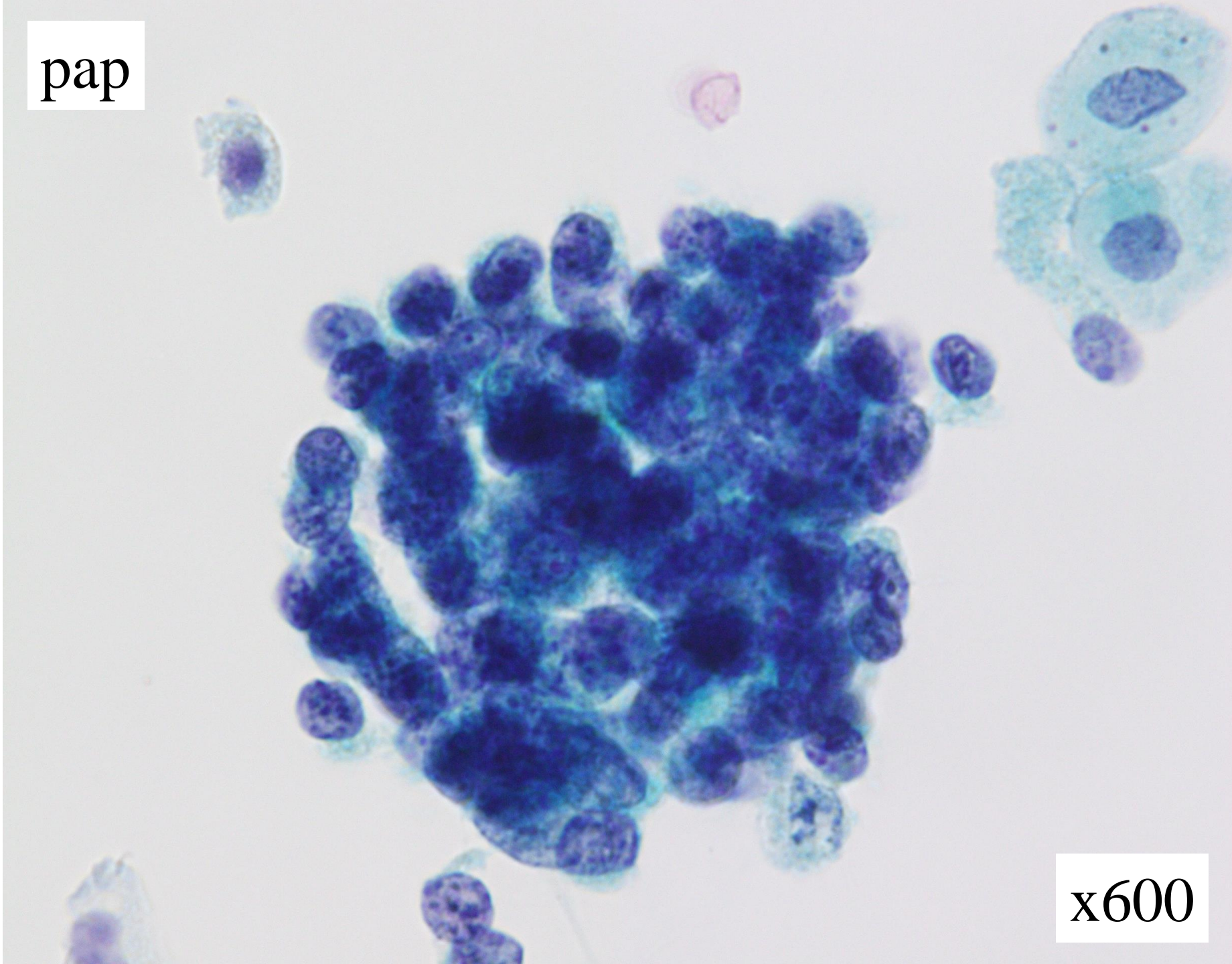
x100

pap



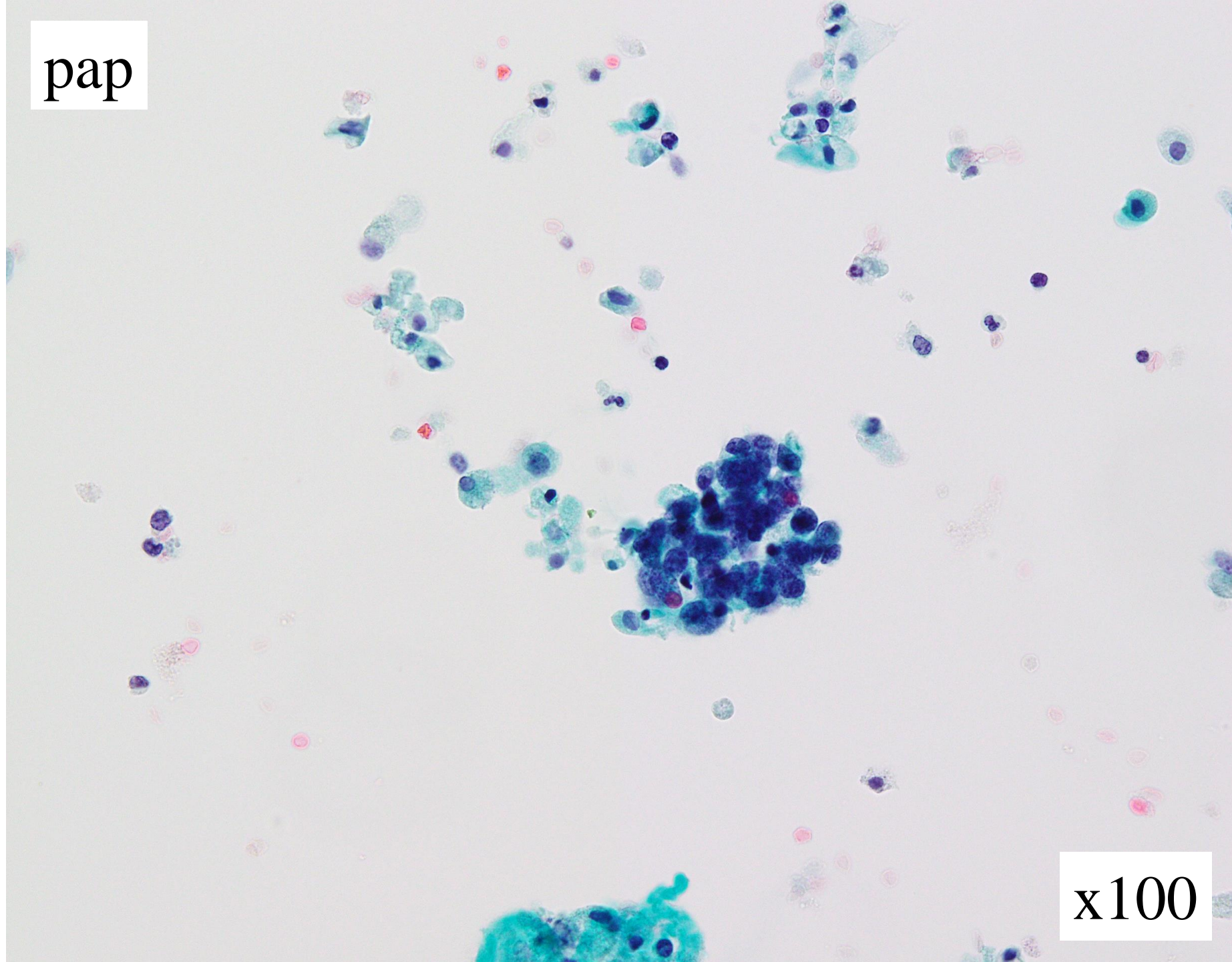
x400

pap



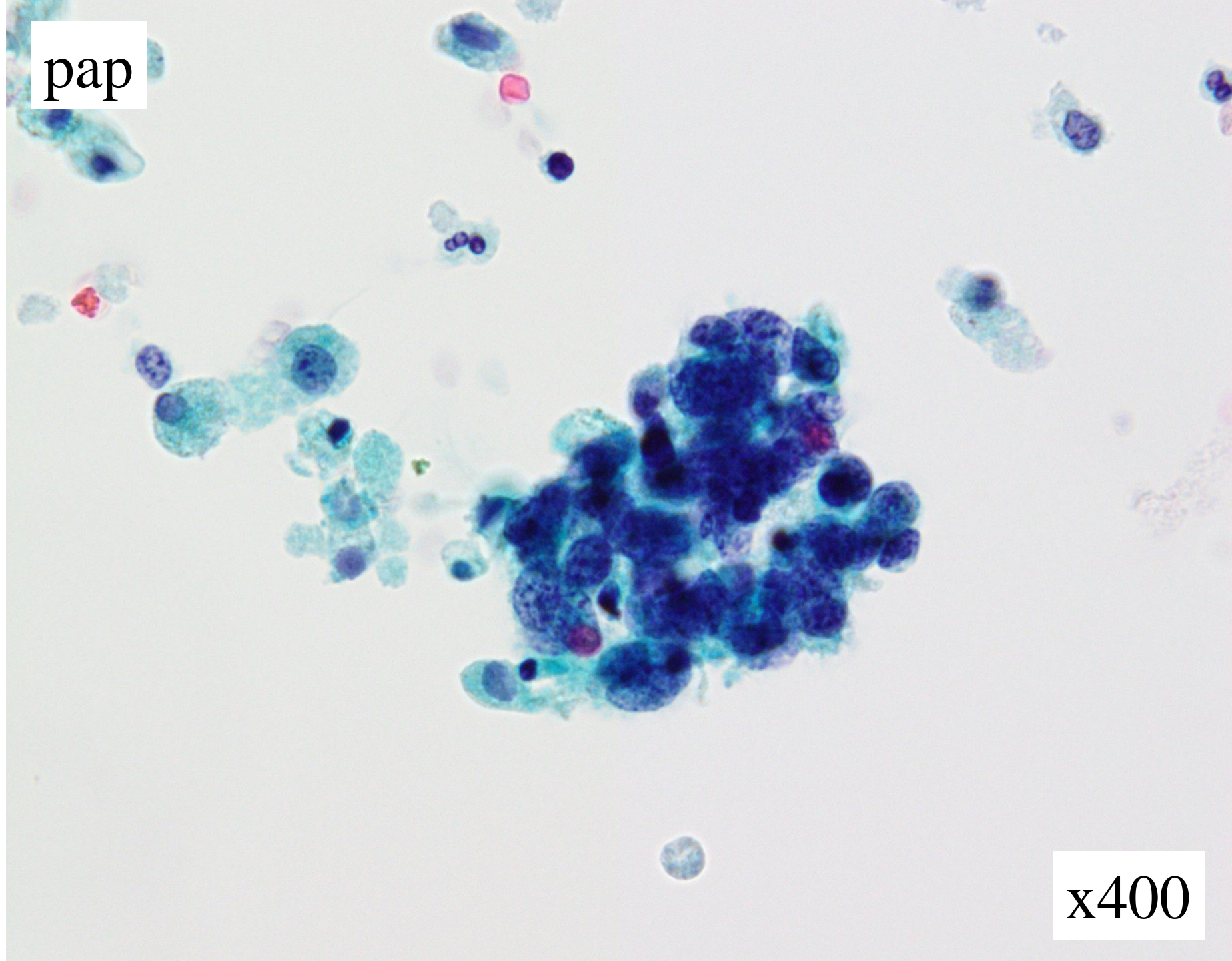
x600

pap



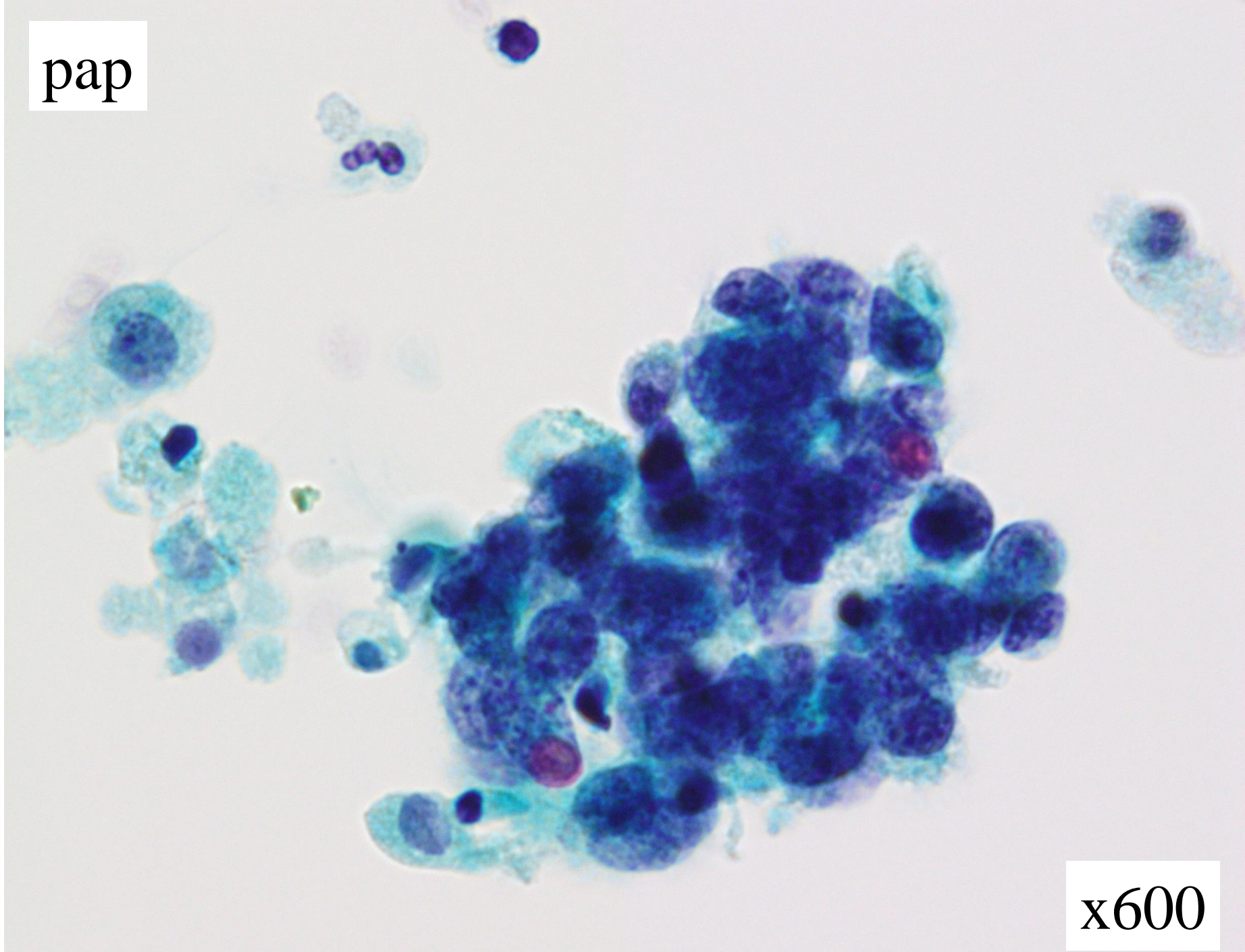
x100

pap



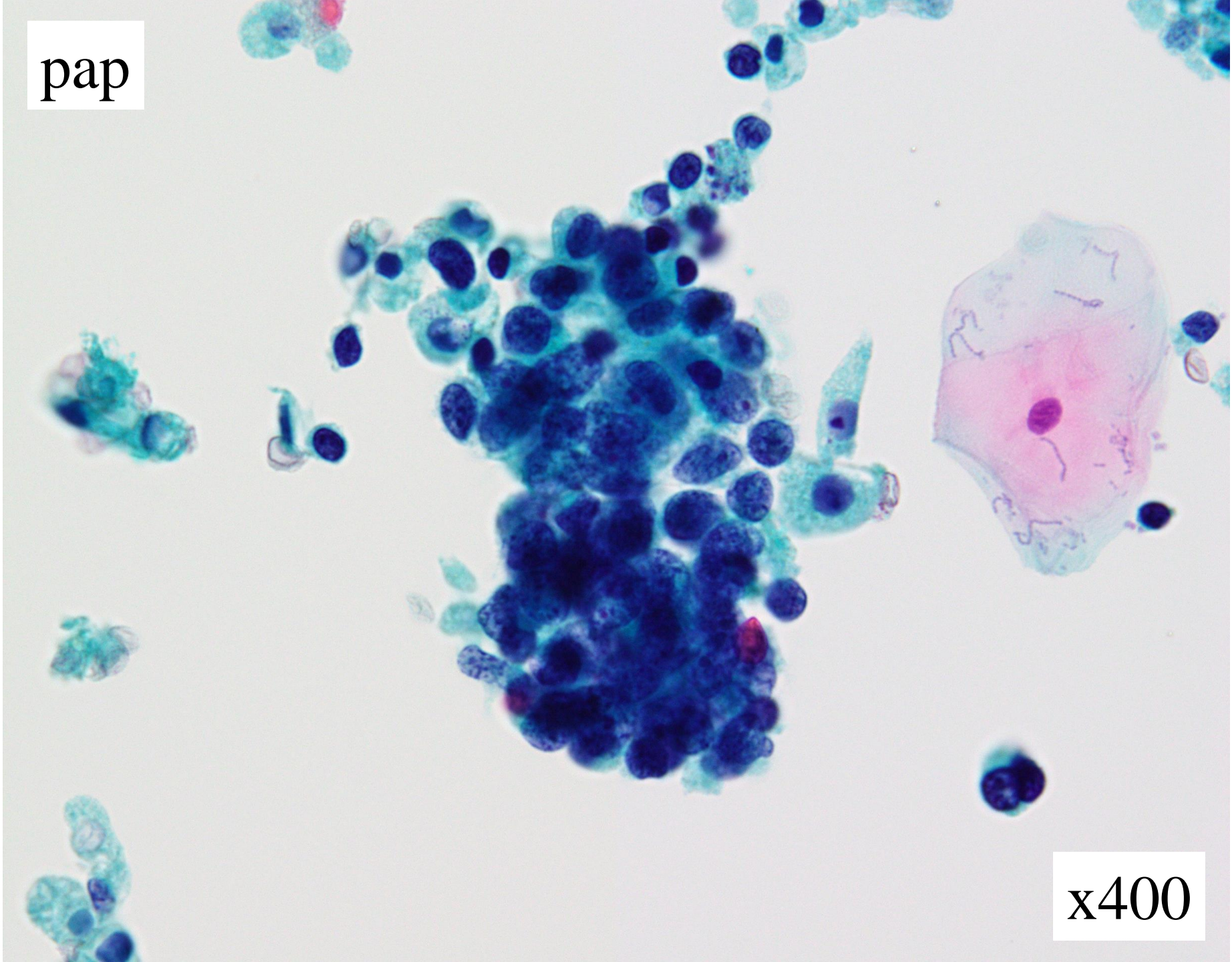
x400

pap



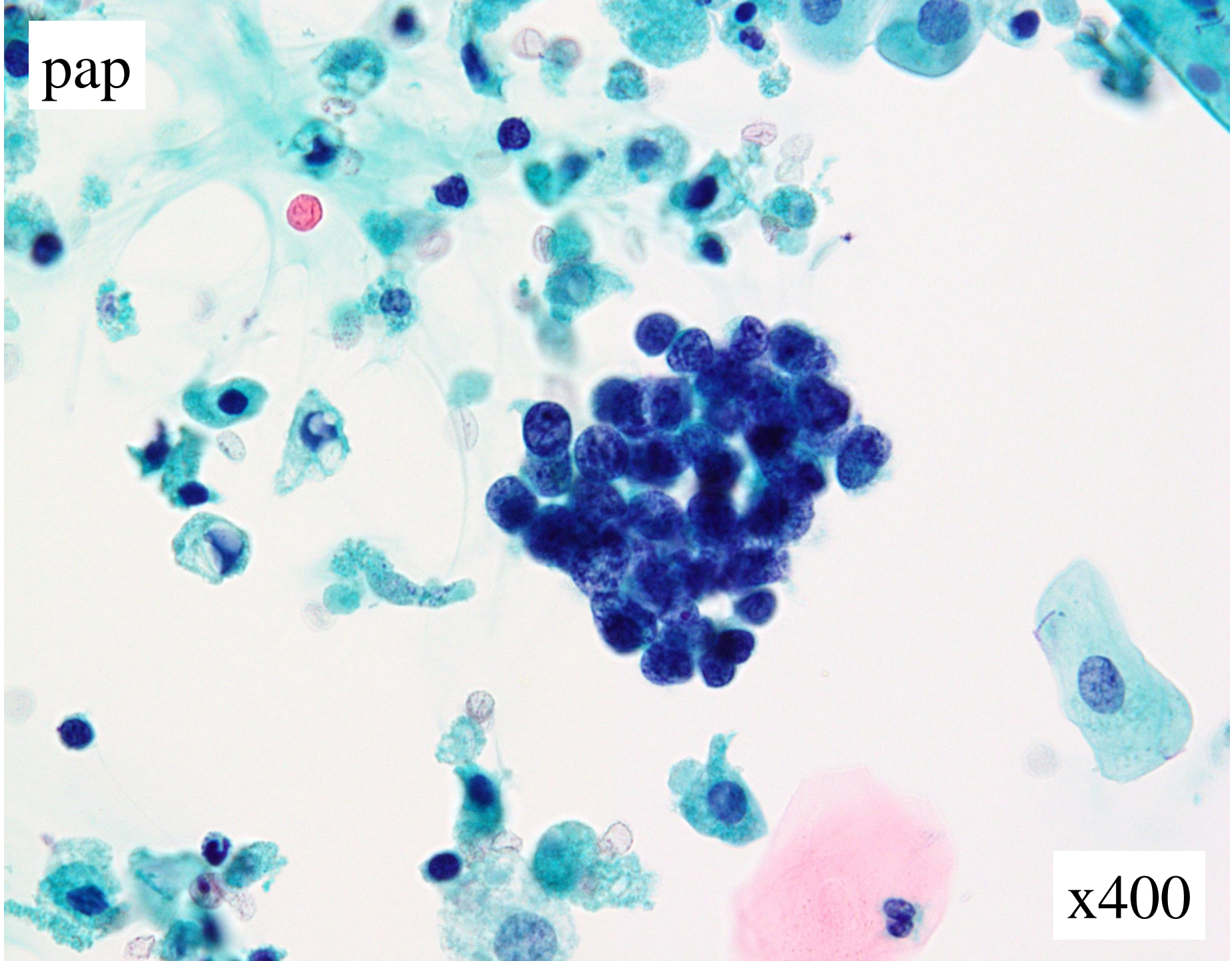
x600

pap



x400

pap



x400

Answer Choices

1. Benign cells (prostate origin)
2. Low-grade urothelial carcinoma
3. High-grade urothelial carcinoma
4. Small cell carcinoma
5. Malignant lymphoma