

# Palpable Breast Mass in a 74-year-old Female

63<sup>rd</sup> Annual Autumn Meeting  
Japanese Society of Clinical Cytology  
Chiba, Japan  
November 16, 2024

***Dr. Hakan Aydin***

Department of Anatomic Pathology  
Sengkang General Hospital, Singapore

# Clinical History - Physical Examination

- 72-year-old female
- Left breast lump for 1 year (increasing in size)
- No pain, no nipple discharge
- Well-circumscribed, retroareolar (10-11 o'clock position)
- 5.0 x 5.0 cm

# Radiology

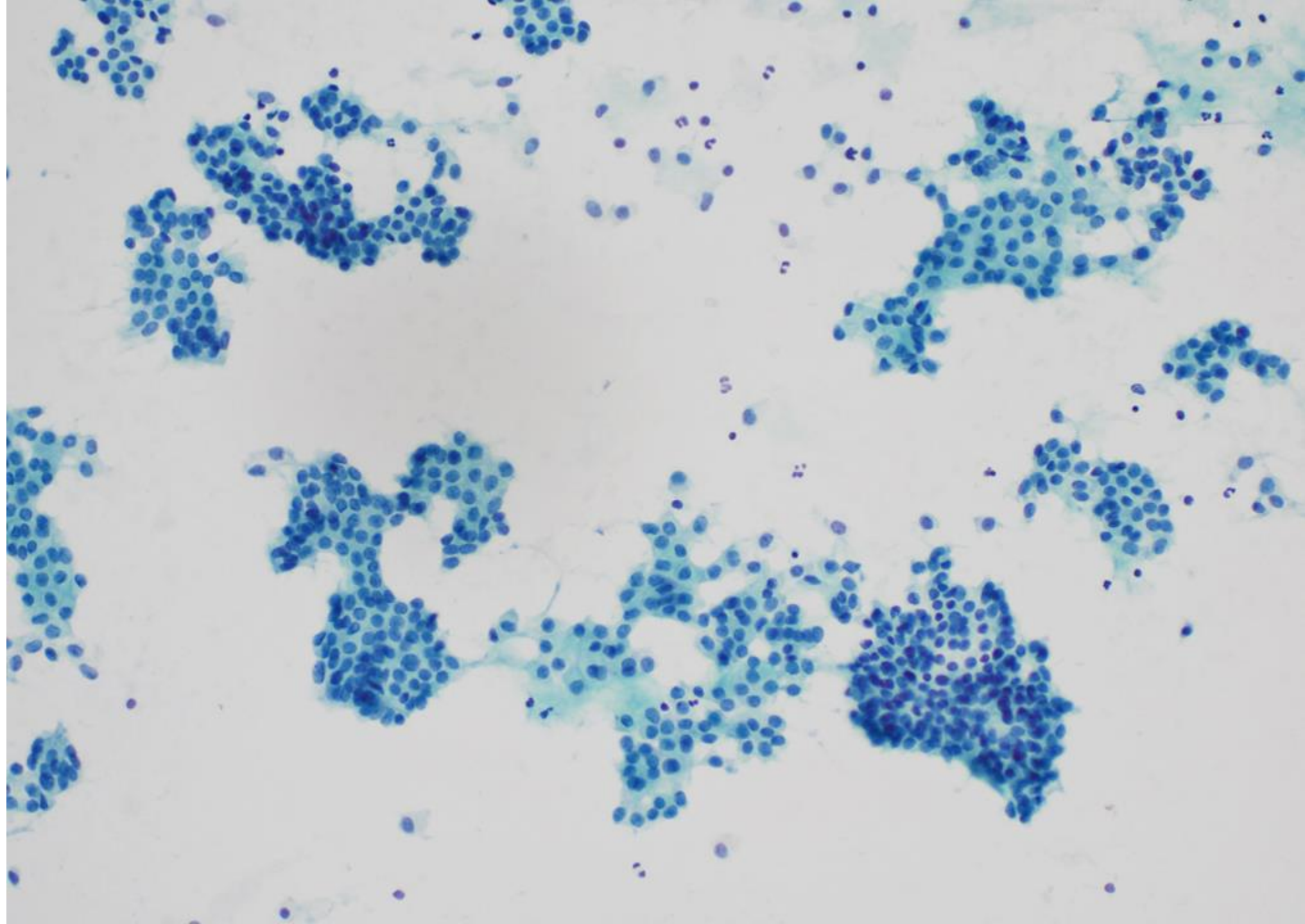
- Mammography
  - Circumscribed, high density mass corresponding to the palpable lump
  - 63 x 57 x 54 mm
- Ultrasonography
  - Solid-cystic mass (suspicious)\*
  - Fine needle aspiration (FNA) and core biopsy performed

\*BIRADS: 4- Suspicious abnormality. Biopsy should be considered.

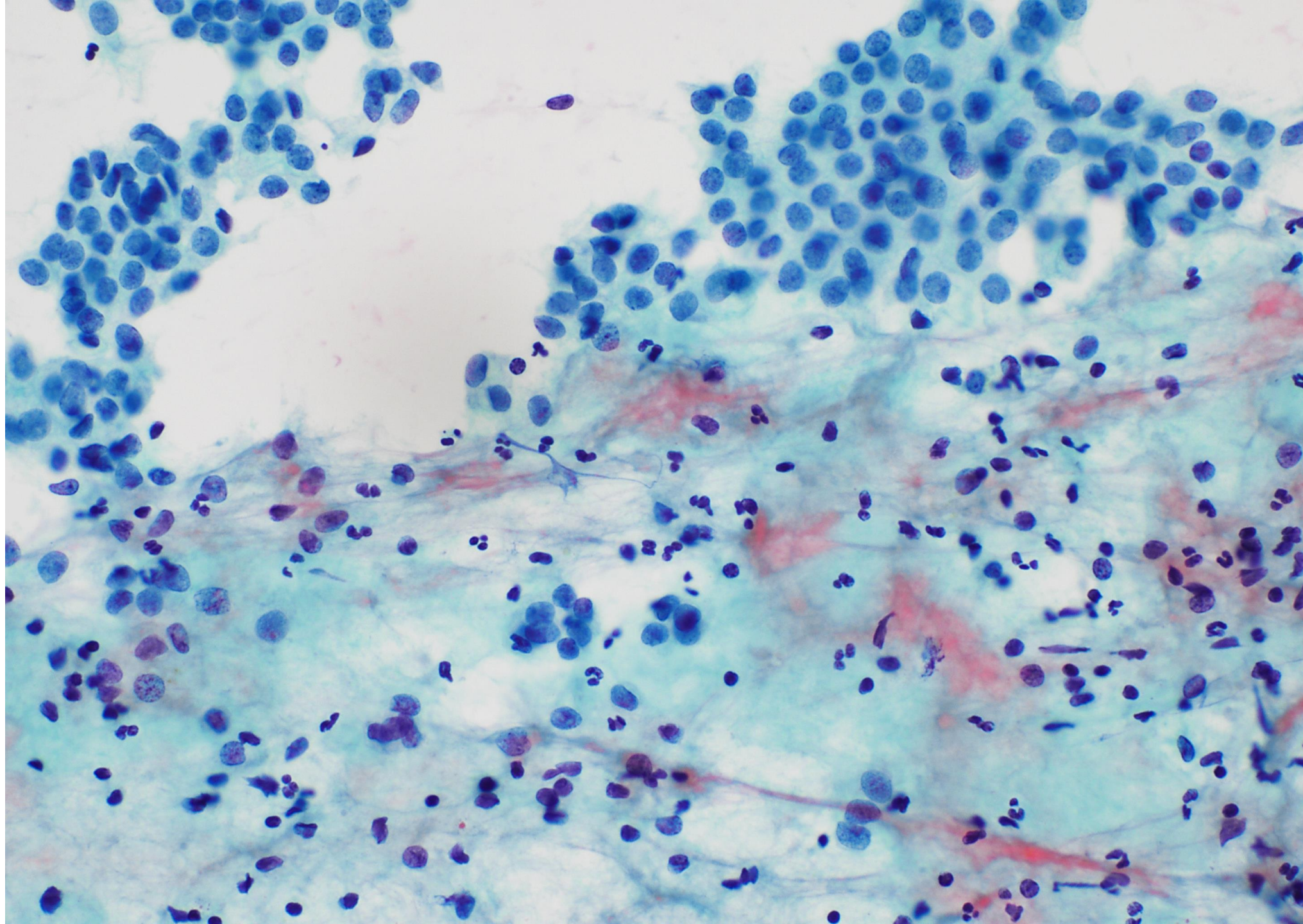
# FNA Images - Papanicolaou (PAP) Stain



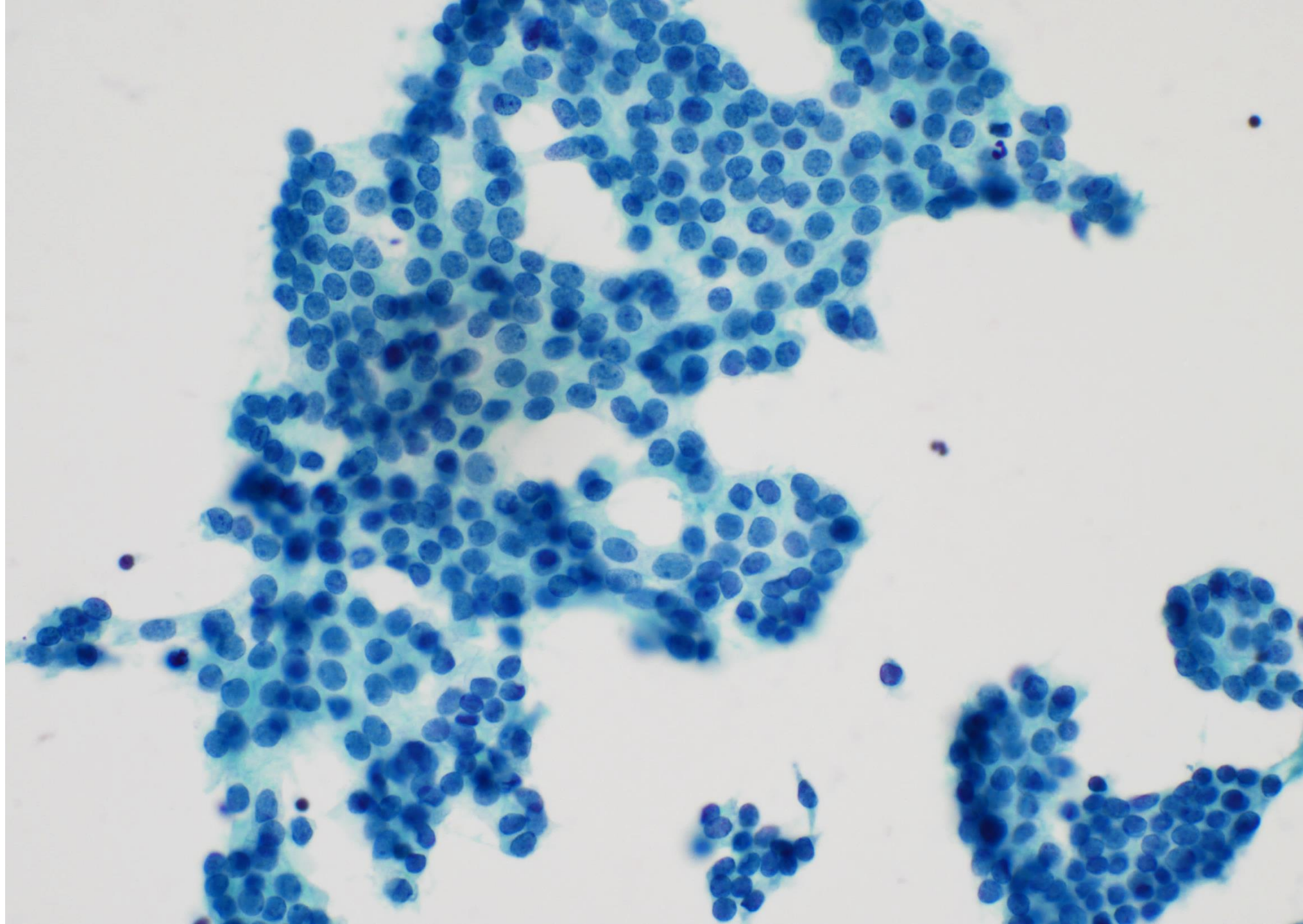






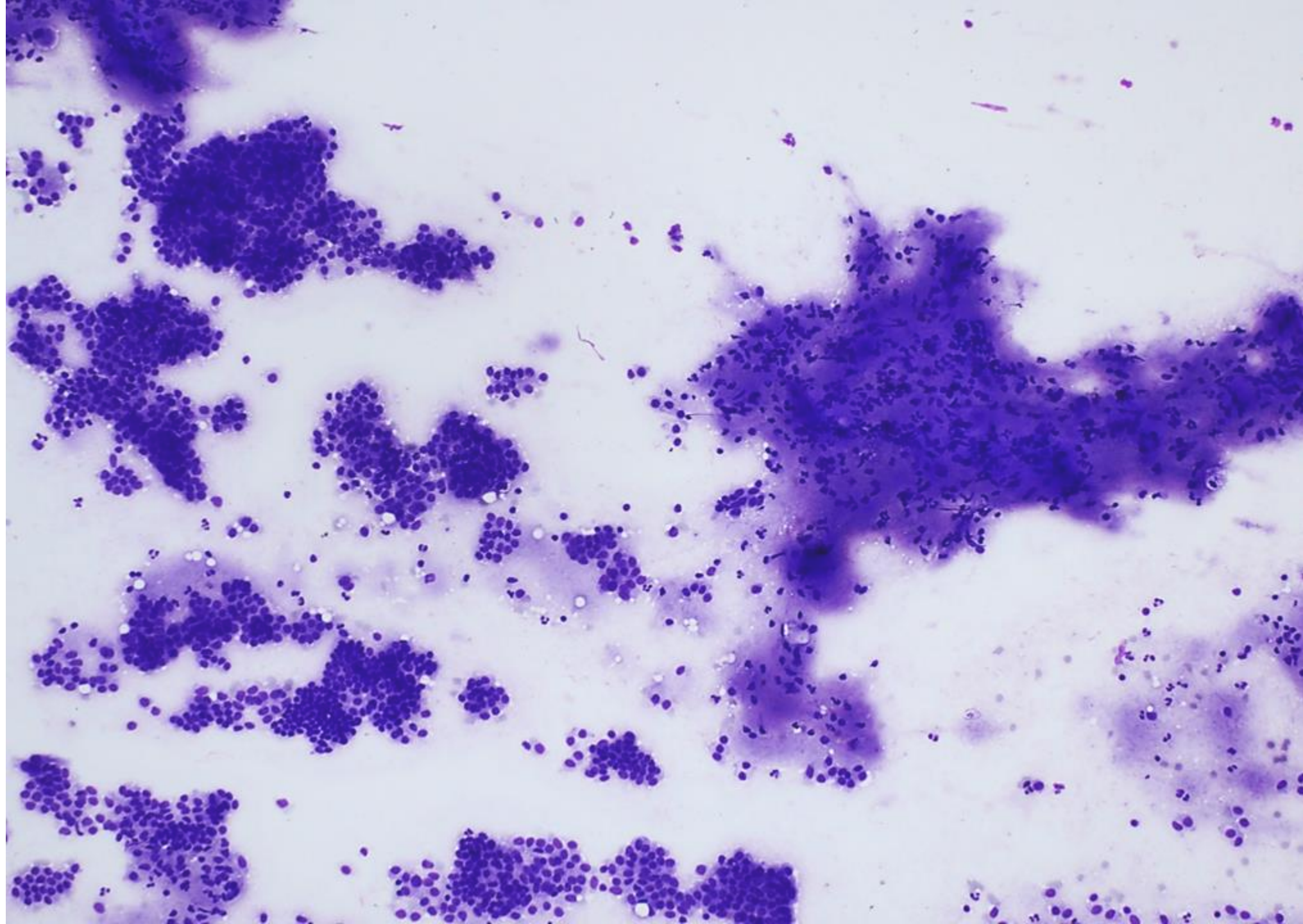




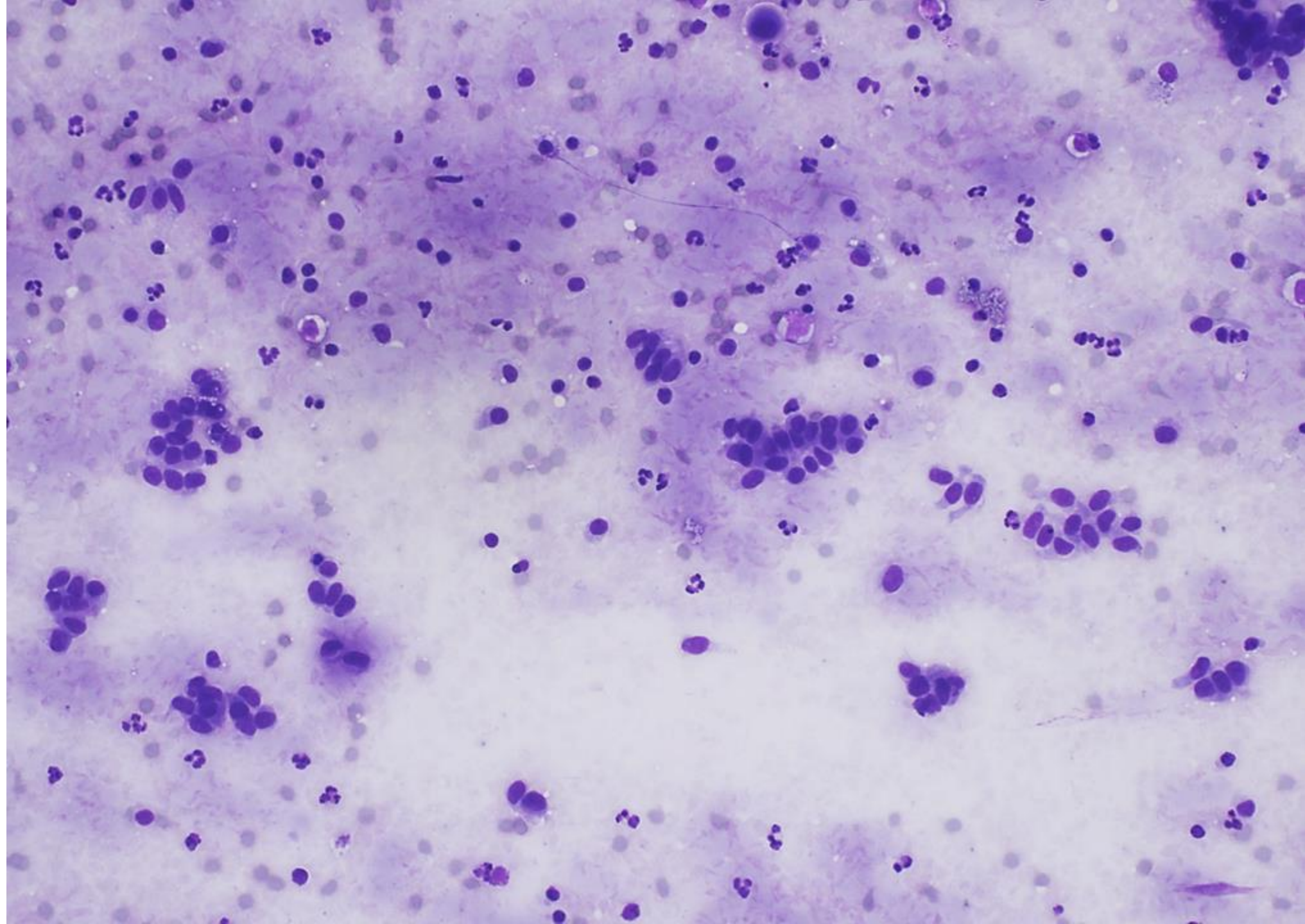




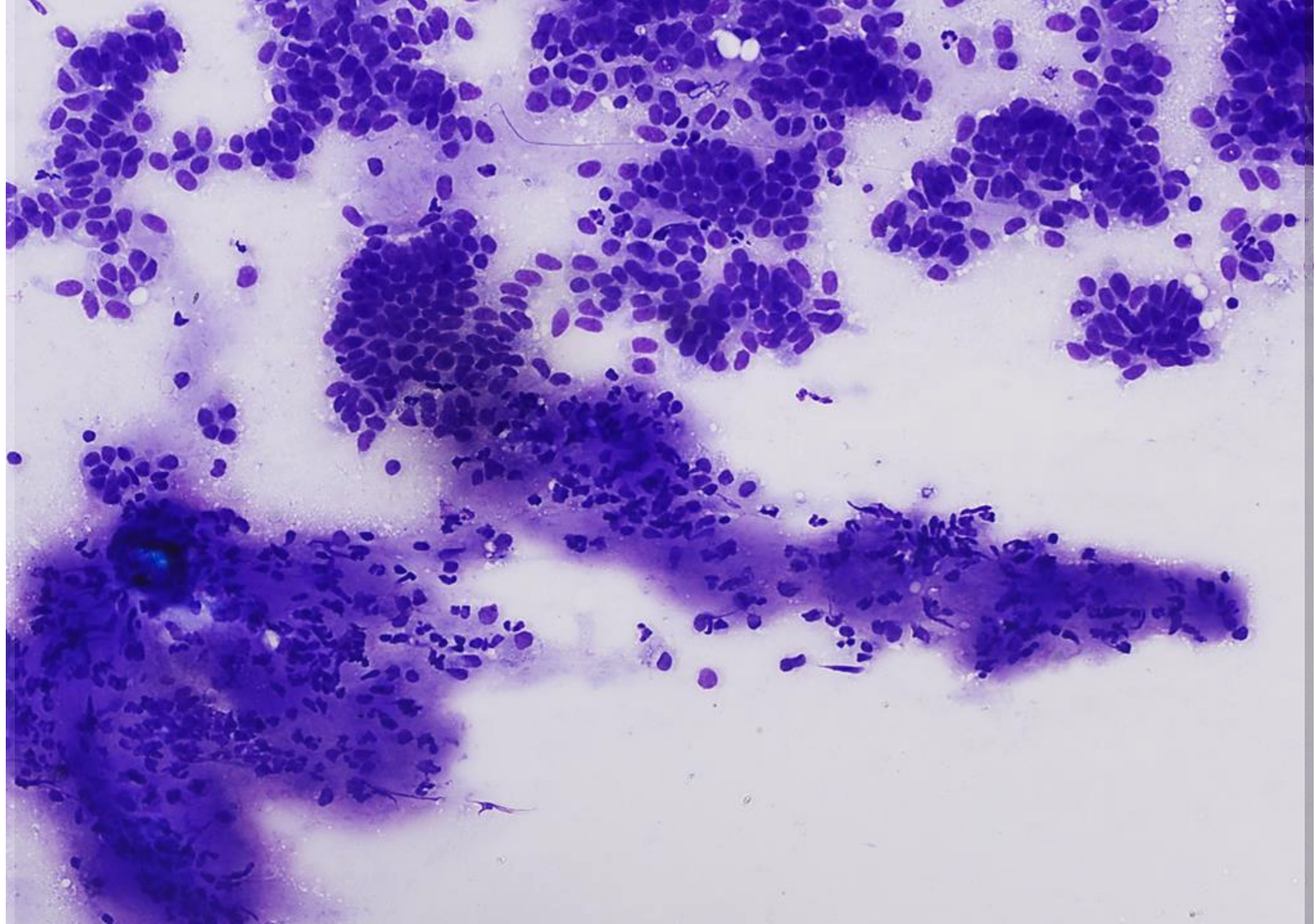
FNA Images - Diff-Quik (DQ) Stain



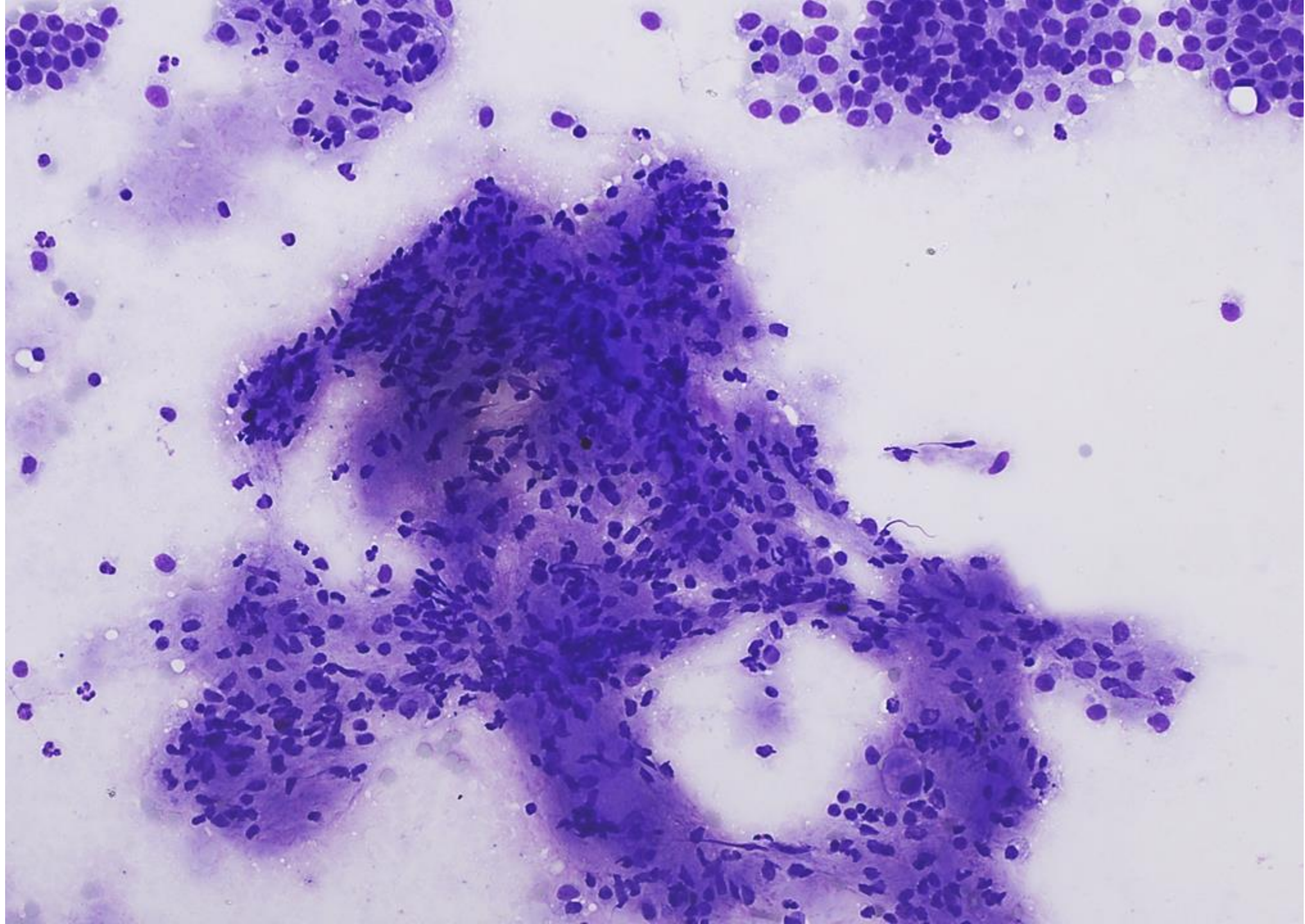




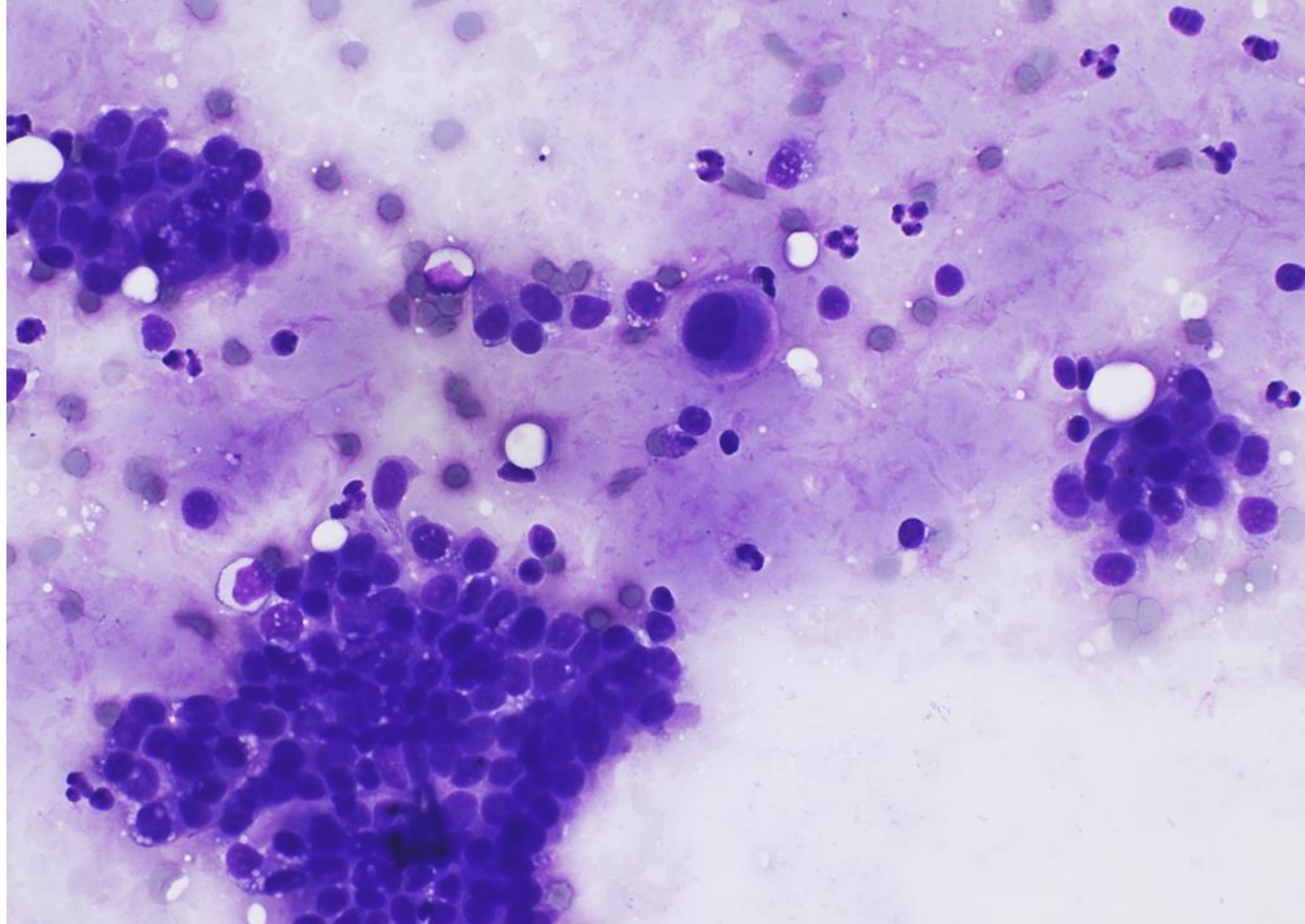














# Diagnostic Options (Categorical with Favored Entity)

- A. Benign (usual ductal hyperplasia)
- B. Benign (intraductal papilloma)
- C. Atypical (fibroepithelial lesion)
- D. Suspicious (papillary lesion)
- E. Malignant (invasive carcinoma)